

CLINICAL IMAGE

Rash on a Child

Chelsea Reynolds, OMS-III¹; Ronald Januchowski, DO, FACOFP¹; Hanna Sahhar, MD

¹Edward Via College of Osteopathic Medicine-Carolinas Campus, Spartanburg, SC

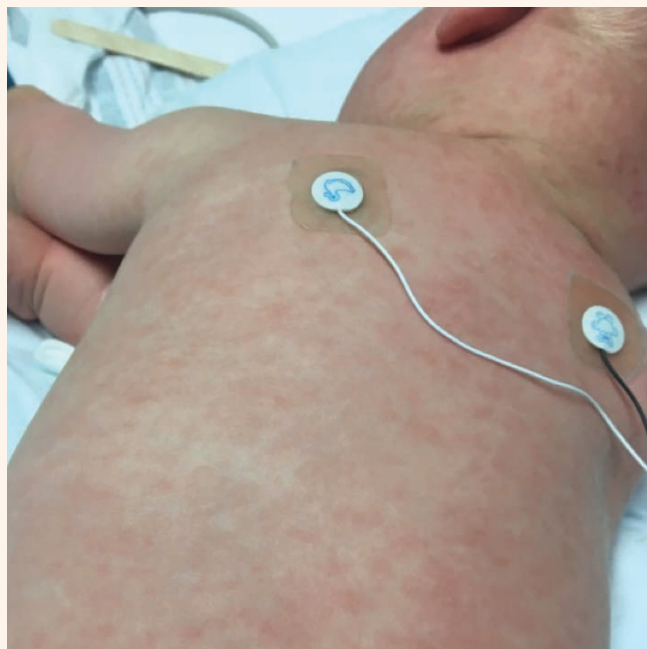
An 11-month-old male presented to the emergency center with a two-day history of worsening cough, conjunctivitis, purulent runny nose, fever and the presence of a maculopapular rash as seen in *Figure 1 and 2*. Patient's mother noted that the rash started on the child's face and progressed down his body. Physical exam showed a diffuse erythematous, maculopapular rash present over the entire body with sparing of the palms and soles. He had

fevers and malaise but denied gastrointestinal symptoms or genitourinary symptoms. The rash faded two days later and followed a similar pattern.

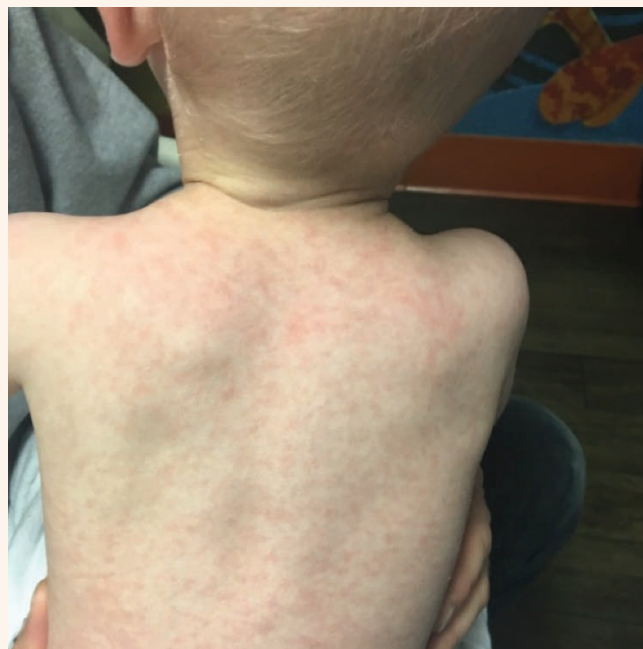Social history includes a trip to Europe a month prior, no prior immunizations and a two-year-old sister with a similar presentation two weeks prior. She also had no prior immunizations.

FIGURE 1:

Rash on trunk of patient

**FIGURE 2:**

Maculopapular rash on trunk of patient

**CORRESPONDENCE:**

Ronald Januchowski DO, FACOFP | rjanuchowski@carolinas.vcom.edu

QUESTIONS:**1. What is the most likely diagnosis?**

- A. Erythema infectiosum
- B. Roseola
- C. Rubeola
- D. Varicella Zoster

2. Besides supportive care, what treatment has been shown to reduce morbidity and mortality for this patient?

- A. Acyclovir
- B. Corticosteroids
- C. Aspirin
- D. Penicillin G
- E. Vitamin A

ANSWERS:**1. What is the most likely diagnosis?**

Correct Answer:
C. *Rubeola*

Rubeola (Measles) is characterized by cough, coryza, conjunctivitis, Koplik spots and the presence of a fever and a maculopapular rash. The rash appears as a non-pruritic, non-painful rash that begins at the hairline and spreads distally sparing the palms and soles. The rash fades in the same direction it appears. An important characteristic of measles infection includes the combination of fever and rash at the same time.

The differential diagnosis of measles includes Kawasaki disease, dengue fever, syphilis, roseola, erythema infectiosum, and primary varicella infection (chickenpox) as well as other viral diseases of childhood. Measles and chickenpox are the only rashes that present with fever along with body rash. Roseola presents as a lacy rash that starts on the trunk and appears after a fever break. Erythema infectiosum (parvovirus B19) is known for its “slapped cheek” rash that is prominent on the face and accompanied by a fever. The patient was brought to urgent care a day prior to being admitted to the hospital and was diagnosed with parvovirus B19. His sister presented two weeks prior with similar symptoms and was diagnosed with roseola. The diagnosis of measles in this case was made by clinical presentation as well as positive IgG testing for the measles virus.

2. Besides supportive care, what treatment has been shown to reduce morbidity and mortality for this patient?

Correct Answer:
E. *Vitamin A*

Supportive care to include hydration is the mainstay of treating measles. Vitamin A supplementation is associated with reduced morbidity and mortality in patients. It can also reduce eye damage and blindness associated with the disease. Dosing is based on age as noted in the discussion.

DISCUSSION

Rubeola, also known as measles, occurs from an infection caused by a single-stranded; negative-sense enveloped RNA virus of the genus Morbillivirus. The virus is transmitted through respiratory droplets. Patients infected will present with a prodrome of fever, anorexia, malaise and the classic triad of coryza, cough and conjunctivitis. One to two days prior to the onset of exanthem, bluish-white papules on an erythematous base can appear on the buccal mucosa mainly behind the molars (also known as Koplik spots). A maculopapular rash appears 3 to 4 days after onset of fever, classically beginning on the face, hairline, and neck. The rash will then spread distally with sparing of the palms of the hands and soles of the feet. The rash fades in the same pattern it appears. Uncomplicated measles generally lasts seven to ten days in immunocompetent individuals.¹

The prevalence of measles in the United States population declined greatly after the introduction of the measles vaccination in 1971, but recent lack of immunization has led to a recurrence of the virus. Measles is highly contagious with up to 90% of susceptible contacts developing the disease.² In 2018-2019, there were 971 confirmed cases of measles infection in the United States.³ Most cases of measles infection are due to improperly or non-vaccinated children, the majority of which are due to immigration from other countries.⁴

Diagnosis is typically clinical although it can be supported with an IgG and IgM antibody test. This test is confirmatory and positive results are mandated to report to the state health department.

Treatment is mainly supportive with the use of fluids for dehydration, acetaminophen to control fever and Vitamin A. The CDC found in a study that the use of Vitamin A decreases the morbidity and mortality in patients with measles infection.⁵ Once daily doses for two doses of oral vitamin A are recommended at the following amounts: infants less than six months of age 50,000 IU/day; age 6-11 months – 100,000 IU/day; and older than one year – 200,000 IU/day.

Complications of measles are more likely to occur in immunocompromised patients, patients less than five years old or greater than 20 years old and malnourished patients, especially those with vitamin A deficiency.⁵ Complications can include diarrhea, otitis media, pneumonia, meningitis, encephalitis and rarely, subacute sclerosing panencephalitis. Keratitis leading to vision loss can also occur. Careful monitoring of the patient must be performed for symptoms concerning for pneumonia or central nervous system infection, such as headache, confusion or vision changes.

CASE DISCUSSION

In this case, confirmation of rubeola was made via IgG rubeola antibody testing and was confirmed with IgM rubeola antibody testing a few weeks later. Treatment was mainly supportive. When the patient developed bilateral otitis media and lower lobe pneumonia, antibiotics were started. After discharge, parents were advised to vaccinate not only the patient, but his sister as well, and to follow up with a primary care physician. While the vaccine is routinely started at 12 months of age, it can be given as young as six months of age for post-exposure prophylaxis or if the child is at a high risk of exposure to the virus, such as with travel to an endemic area, such as with this case. The vaccine should be given within 72 hours of exposure. Alternatively, immunoglobulin can be used within six days post-exposure for immunocompromised individuals, pregnant females without evidence of measles immunity or infants less than 12 months of age. The vaccine and immunoglobulin should not be administered together, as this would cause the vaccine to be invalidated.⁶

Measles is a complex disease process. This photographic clinical case is meant to illustrate the basic presentation and progression of the disease in pictures and is not intended to cover all of the intricacies of this infectious process.

AUTHOR DISCLOSURES:

No relevant financial affiliations or conflicts of interest.

REFERENCES:

1. Centers for Disease Control and Prevention. "Measles: Epidemiology and Prevention of Vaccine- Preventable Disease," 13th Edition. (2015). 209-230.
2. Marc dante, Karen J., Kliegman, Robert, M. "Nelson Essentials of Pediatrics- Eighth Edition." Philadelphia (PA). Elsevier Saunders. 2019. 97: 373-375
3. Center for Disease Control and Prevention. "Cases and Outbreaks: Measles Cases in 2019". (2019).
4. Alexander, KC., KL Hon, KF Leong, CM Sergi. "Measles: A disease often forgotten but not gone." Hong Kong Academy of Medicine. (2018): 512-20.
5. Centers for Disease Control and Prevention. "Complications of Measles." (2018).
6. American Academy of Pediatrics. Measles. Pickering LK, ed. Red Book: Report of the Committee on Infectious Disease. 31st Edition. Elk Grove, Ill: AAP; 2018-2021. 537-550.